

Cardiac Sonographer Network News

1.800.443.9898 childrenshospitalofil.org

Welcome

Number 5

Welcome to the newsletter created just for you: sonographers who perform pediatric echocardiograms in primarily adult echo labs. Each issue features tips on echocardiography of congenital heart disease, short case reports, congenital heart center news, and information on upcoming educational programs.

In an effort to be “green,” we send this newsletter as an electronic file each quarter. If you or any of your colleagues would like to be on our distribution list, please send an email to:

gregory.b.frary@osfhealthcare.org

Please include your name and facility affiliation.

Copies of all our newsletters can also be accessed on our website at <http://www.childrenshospitalofillinois.org/services-and-clinics/specialty-services/congenital-heart-center/>, then under “Programs”, click on “Sonographer Newsletters”.

We want you to be successful in performing studies even on newborns that may have critical heart disease. After all, prompt diagnosis and emergency treatment will yield the best outcome for our patients. If you have any questions regarding necessary views or anatomy while doing an emergent echo, please call the Congenital Heart Center “on call” cardiologist. They will always be glad to speak with you. The “on call” cardiologist can be reached by calling 309.655.7257 or 309.624.9188.

Lets Have Some Fun

To win some Not So Fabulous Prizes, be the first to answer the following questions. Anyone that receives this newsletter can answer, but note that employees of OSF Healthcare aren't eligible to win any Not So Fabulous Prizes. All questions must be answered fully and correctly to win. Send your answers to Greg at the above e-mail address. The winners will be recognized in the next CSNN:

The background of the Cardiac Sonographer Network News masthead is a diagnostic image:

- 1)What modality is this image?
- 2)What diagnosis can be made from this image?
- 3)What congenital heart disease **most likely** would cause this finding?

Sonographer Tip

Imaging the Adult With Repaired Tetralogy of Fallot

Due to the excellent results from repair of congenital heart disease, there are now more adults than children with congenital heart disease living in the United States! These patients are now well into the age where acquired heart disease will be rearing its ugly head, and it is highly likely that you will be asked to image one of your adult patients that has had repair of some sort of congenital heart disease.

The repair of Tetralogy of Fallot (TOF) has now been performed routinely and successfully since 1981, but the first successful repair was performed on an 11 year old boy by C. Walton Lillehei, MD at the University of Minnesota in 1954! So, there are many patients walking around with repaired TOF in their 40s, 50s, and even older.

What is Tetralogy of Fallot?

- 1-Ventricular septal defect (VSD) in the peri-membranous area
- 2-Overriding of the aorta anterior to the inter-ventricular septum (anterior mal-alignment of the aorta)
- 3-Right ventricular hypertrophy
- 4-Right ventricular outflow tract (RVOT) obstruction at the sub-valve, valve, or supra-valve (or combination of) levels

How is Tetralogy of Fallot repaired?

- 1-Patch closure of the VSD
- 2-Relief of the RVOT obstruction by any number of techniques including trans-annular patch and/or valved conduit

As in most cases of congenital heart disease surgery, repair is only palliation and not a complete cure. Surgical success and long-term outcome depend on the particular anatomy of the patient and the surgeon's skill and experience. A vast majority of patients with total repair develop progressive pulmonary valve insufficiency later on in life, and require follow up in a specialized adult congenital heart disease center.

What should we look for with echocardiography?

Obviously, your lab's routine protocol for an adult should be used on all of your patients. In addition, you must also do a targeted study for a post-operative TOF. The targets for the study are the RV, the RVOT, the pulmonary valve, and the branch pulmonary arteries. You should image the VSD patch and interrogate it with color flow mapping (CFM), but patch failure is very rare after the immediate post-operative period. The CHOI Congenital Heart Center protocol is as follows:

Parasternal Short Axis (PSAX)

1-M-mode with measurement of the RV at end diastole

2-2D measurement of the RVOT, (Figure 1) the pulmonary annulus, and the MPA

3-CFM of the RVOT, pulmonary annulus, and the MPA

4-Full spectrum CW tricuspid regurgitation (TR) jet for RVSP

5-Pulsed Doppler (PW) of the RVOT, the pulmonary insufficiency (PI) jet, and MPA

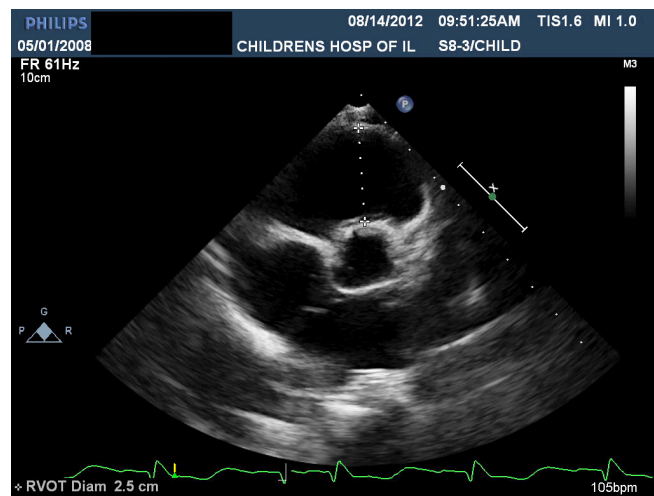


Figure 1

Measurement of the PI jet should include the pressure half-time and the end diastolic velocity

6-Continuous Doppler (CW) of any stenotic jet through the pulmonary valve.

Technical hint: The best location for the PI and PS jet may be a little lower on the chest between the parasternal window and the apical window. Also, always try to obtain the PS and PI jet from the subcostal window

Apical (A4ch)

1-2D measurements at end diastole of tricuspid valve annulus, RV length from apex to TV annulus plane, and the mid-RV diameter (see figure 2)

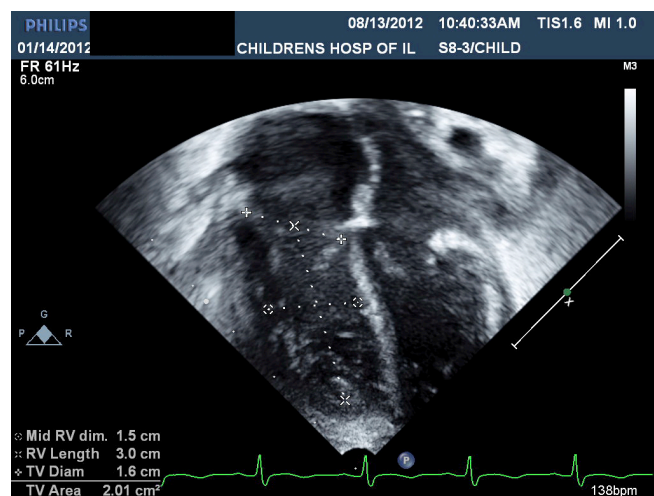


Figure 2

2-2D trace of RV endocardial border at peak systole and end diastole to figure fractional area change (FAC) (see figure 3)

3-M-mode of Tricuspid Annular Peak Systolic Excursion (TAPSE) (see figure 4)

4-Full spectrum CW TR jet for RVSP

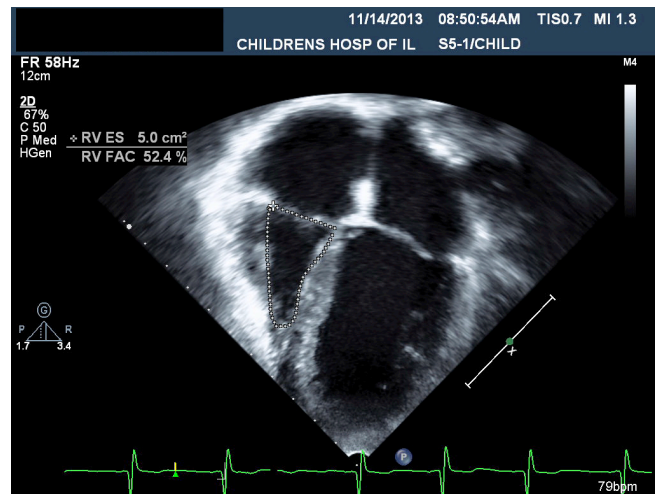


Figure 3

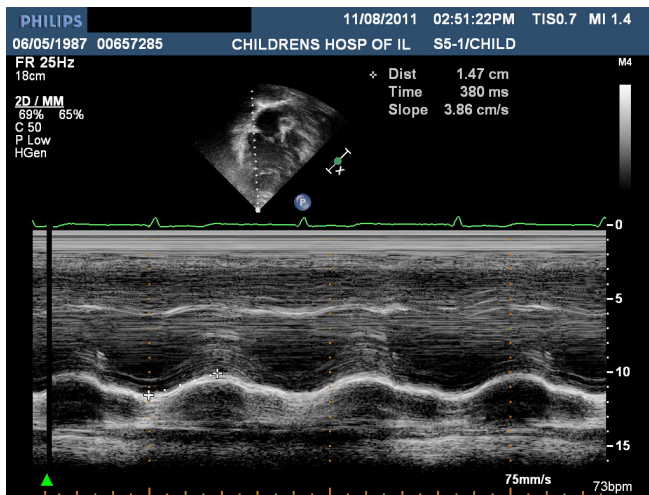


Figure 4

Subcostal

1-Continuous Doppler (CW) of stenotic jet through the pulmonary valve.

2-Full spectrum CW TR jet for RVSP

Suprasternal or High Left Parasternal

1-2D measurement of RPA and LPA diameter in systole

2-CFM and PW in branch for determination of systolic and diastolic flow

Save the Date

Coming March 1, 2014

Demystifying Fetal Echocardiography