

# Cardiac Sonographer Network News

1.800.443.9898 [childrenshospitalofillinois.org](http://childrenshospitalofillinois.org)

## Welcome

## Number 6

Welcome to the newsletter created just for you: sonographers who perform pediatric echocardiograms in primarily adult echo labs. Each issue features tips on echocardiography of congenital heart disease, short case reports, congenital heart center news, and information on upcoming educational programs.

In an effort to be “green,” we send this newsletter as an electronic file. If you or any of your colleagues would like to be on our distribution list, please send an email to:

[gregory.b.frary@osfhealthcare.org](mailto:gregory.b.frary@osfhealthcare.org)

Please include your name and facility affiliation.

Copies of all our newsletters can also be accessed on our website at <http://www.childrenshospitalofillinois.org>. Click on “Services and Clinics” in the middle then under “Specialty Services”, click on “Cardiology/Congenital Heart Center”, then under “Programs”, click on “Sonographer Newsletters”.

We want you to be successful in performing studies even on newborns that may have critical heart disease. After all, prompt diagnosis and emergency treatment will yield the best outcome for our patients. If you have any questions regarding necessary views or anatomy while doing an emergent echo, please call the Congenital Heart Center “on call” cardiologist. They will always be glad to speak with you. The “on call” cardiologist can be reached by calling 309.655.7257 or 309.624.9188.

## Let's Have Some Fun (Again!)

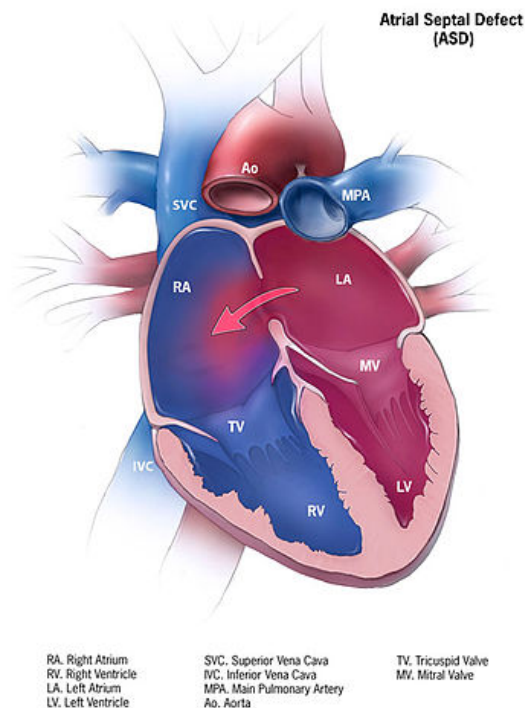
The last newsletter asked everyone the following questions. We had three responses. Two were incorrect, and one was partially correct. So, we are changing it from “Not So Fabulous Prizes” to win some “Fabulous Prizes”. Be the first to answer the following questions. Anyone that receives this newsletter can answer, but note that employees of OSF Healthcare are not eligible for prizes. All questions must be answered fully and correctly to win. Send your answers to Greg at the above e-mail address. The winners will be recognized in the next CSNN and at our Fall 2015 meeting:

The background of the Cardiac Sonographer Network News masthead is a diagnostic image:

- 1) What modality is this image?
- 2) What diagnosis can be made from this image?
- 3) What congenital heart disease *most likely* would cause this finding?

## Save The Date

The Midwest Pediatric Cardiology Society (MPCS) annual meeting is being hosted by Children's Hospital of Illinois. It is to be held Thursday and Friday September 10-11, 2015. In conjunction with the MPCS, The Congenital Heart Center at Children's Hospital of Illinois is hosting the Annual Midwest Cardiac Sonographer Society (MCSS) meeting immediately following on Saturday September 12, 2015. Echocardiography of congenital heart disease from the infant to the adult will be discussed. Look for more information and registration in the coming months.



## Sonographer Tip

### Imaging the Atrial Septal Defect (ASD)

There are three kinds of atrial septal defects. They are: sinus venosus, ostium secundum, and ostium primum. For this discussion, we will talk only about ostium secundum defects as these are the most prevalent. The ostium secundum type ASD is also the one that is most often closed by catheter intervention rather than surgical closure. When performing an echo on your patient with an ASD, specific measurements must be made to determine the suitability of closure by a catheter device. Sufficient “rims” around the defect are necessary for the device to be effective. (See Figure 1 for “rim” definition)

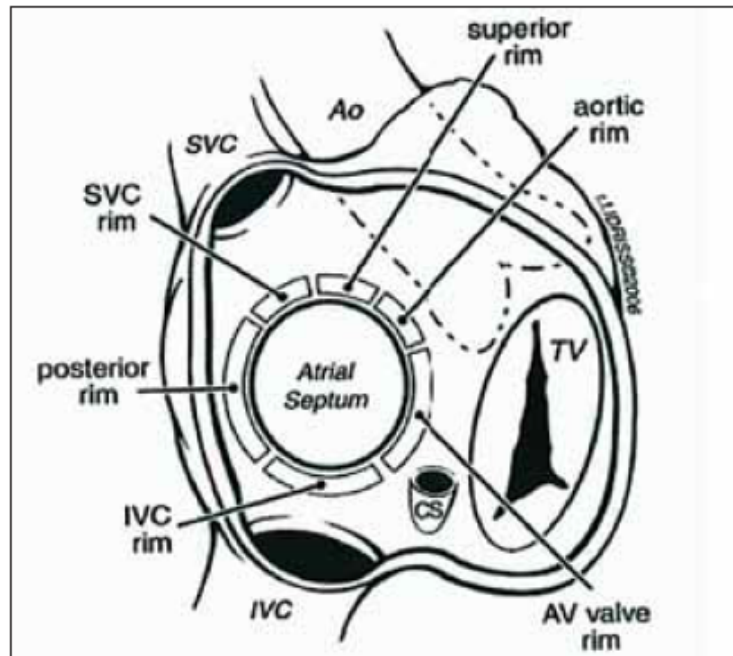


Figure 2. Classification of atrial septal rims. Reprinted with permission from Amin Z. Catheter Cardiovasc Interv 2006;68:778–787.<sup>1</sup>

Figure 1. Rim Definition

## 2D Measurements for Patients That May Receive ASD Occluder Devices

The following procedure should be used when performing a study on a patient that may undergo implantation of an ASD occluder device. Two-dimensional (2D) measurements should be made in three different 2D views; Parasternal Short Axis (SA), Apical 4 Chamber (A4), and Subcostal Bi-Caval (BC) views.

- A SA view should be obtained in such a way that shows the anterior rim (aortic), the defect, and the posterior rim. (See Figure 2)

The measurements to be made are:

SA Ant. (aortic) Rim

SA Defect Size

SA Posterior Rim

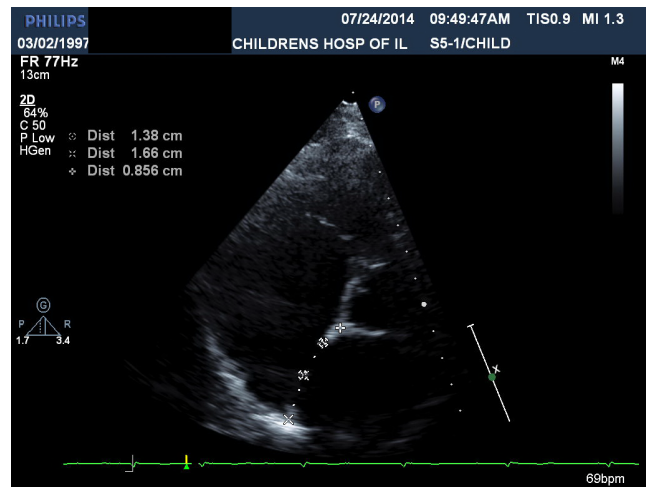
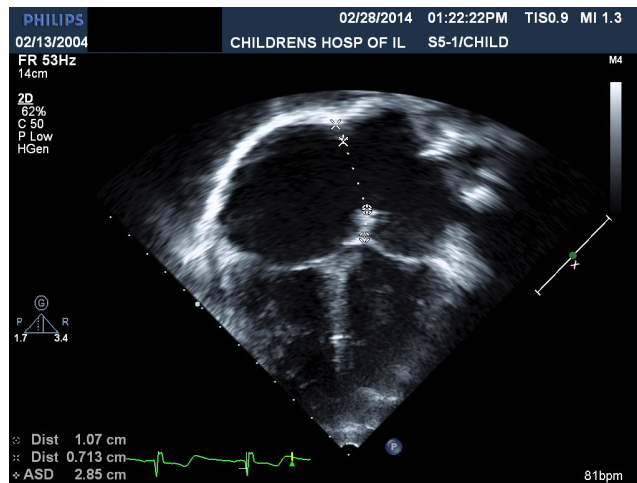


Figure 2. Parasternal Short Axis



- An A4 view should be obtained in such a way as to show the superior rim, the defect, and the inferior rim. (See Figure 3)

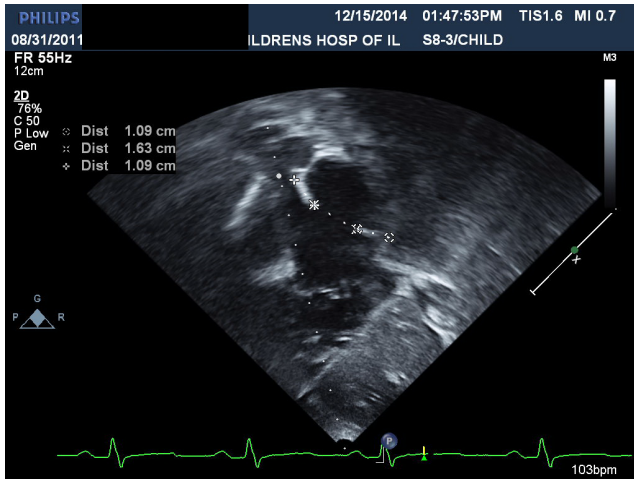
The measurements to be made are:

A4 Posterior Rim

A4 Defect Size

A4 AV Valve Rim

Figure 3. Apical 4 chamber



•A BC view should be obtained in such a way that shows the superior rim, the defect, and the inferior rim. (See Figure 4)  
 The measurements to be made are:

- BC Superior Rim
- BC Defect Size
- BC Inf. Rim

Fig 4. Subcostal Bi-Caval